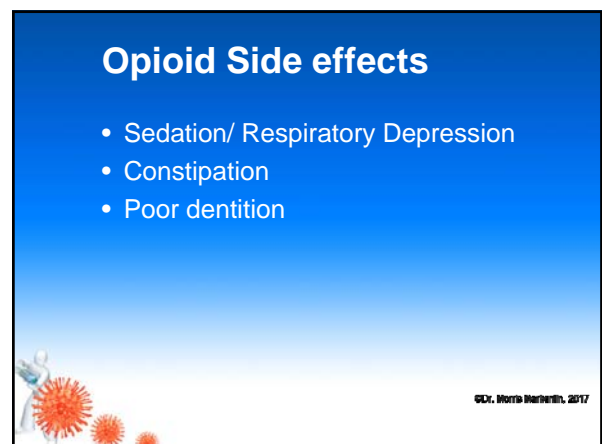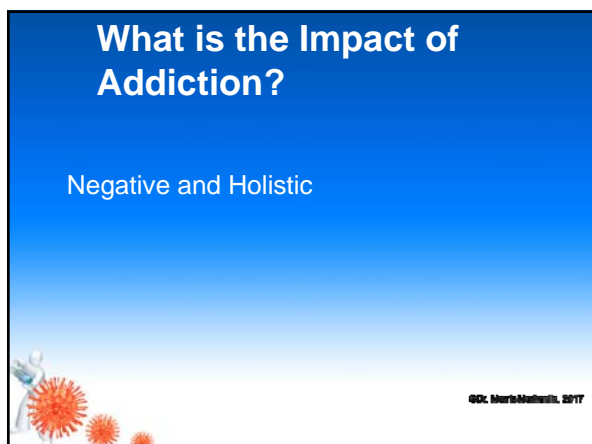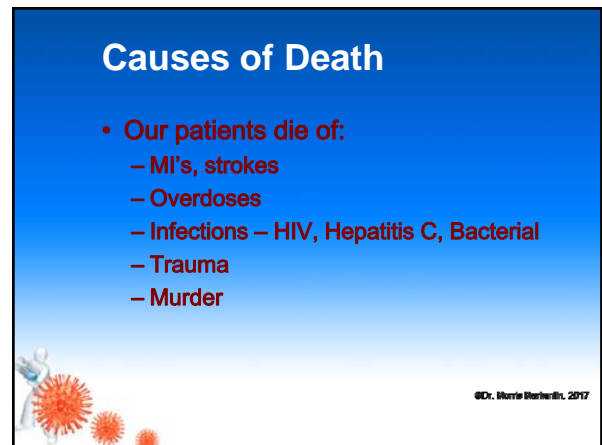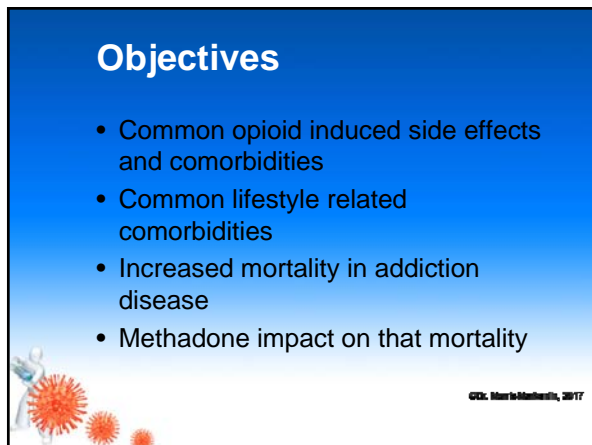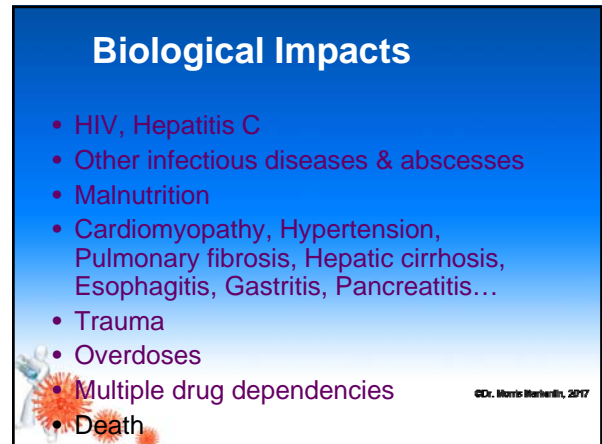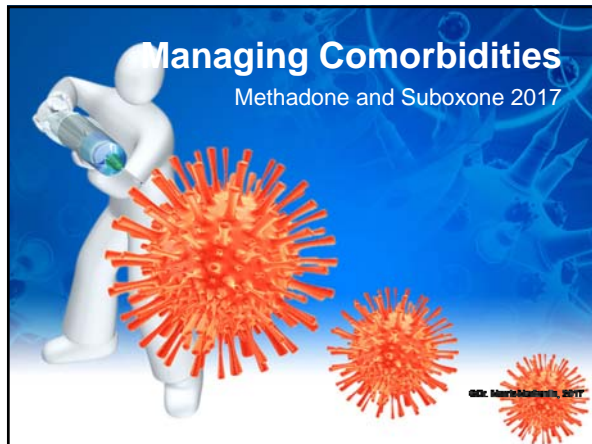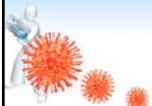


Skin

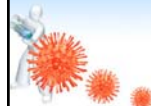
- MRSA common
- Abscesses
- Chronic ulcers
- Scabies
- Bed bug bites



©Dr. Morris Markstein, 2017

Case 1

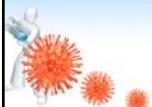
- Needs antibiotic – refuses to go to hospital
- Cover for MRSA
- Trial of Bactrim DS 1 tab po bid
- Follow up in 24 hours



©Dr. Morris Markstein, 2017

Case 1

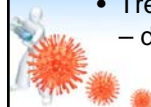
- 30 y.o female presents with complaint of fever and chills
- Complaining of pain in her left forearm
- She is wearing long sleeved shirt
- Refuses to pull up her sleeves



©Dr. Morris Markstein, 2017

HIV

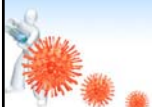
- A chronic viral infection
- Treatable to the point of patients able to live a normal lifespan
- Methadone allows for stability
- Allows for diagnosis, engagement and treatment
- Treatment – non detectable viral load – decreased spread



©Dr. Morris Markstein, 2017

Case 1

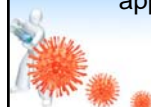
- Large abscess size of egg on her forearm
- Local anesthetic and drained for copious amount of purulent fluid
- C and S



©Dr. Morris Markstein, 2017

HIV

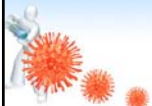
- Treating addiction opens the door to testing for HIV and Hep C
- Patients may not get tested otherwise
- Addiction treatment engages patient into care
- Methadone allows for regular appointments



©Dr. Morris Markstein, 2017

HIV

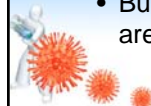
- Like other chronic diseases – regular blood work necessary – q3 months
- CD4, viral load,
- Need to monitor renal function as well if on antiretroviral therapy



©Dr. Morris Berkstein, 2017

Hepatitis C

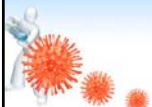
- Methadone allows for stability and the ability to treat.
- Genotype 1,2 now 99% cure rates
- Genotype 3 98% cure rates
- Methadone allows for adherence, cure will decrease spread if relapse
- Burden of liver disease projections are huge



©Dr. Morris Berkstein, 2017

Case 2

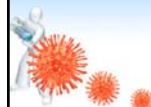
- 23 y.o female presents for methadone induction
- Only uses opiates
- Screening blood work offered and patient agrees to have it done



©Dr. Morris Berkstein, 2017

Hepatitis C

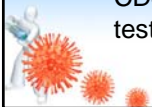- Treatment is expensive
- Once cured can reinfect
- Stability is important prior to treatment
- Methadone allows for that stability



©Dr. Morris Berkstein, 2017

Case 2

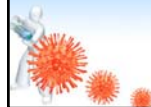
- Western Blot comes back HIV positive
- Patient follows up for methadone induction
- Time spent discussing diagnosis
- Initial blood work obtained including CD4/CD8, viral load and resistance testing



©Dr. Morris Berkstein, 2017

Case 3

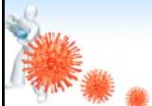
- 36 y.o. male stable on methadone for 1 year
- Chronic Hepatitis C
- Genotype 1
- Viral load 600,000
- Fibroscan F3



©Dr. Morris Berkstein, 2017

Case 3

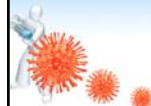
- Patient qualifies for ledipasvir/sofosbuvir
- 8 weeks treatment
- End of treatment HCV viral load non detectable



©Dr. Morris Berkstein, 2017

Case 4

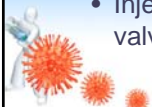- 27 y.o female HIV positive IVDU off and on methadone 3 times in past year
- Ongoing opiate and stimulant use



©Dr. Morris Berkstein, 2017

Infective Endocarditis

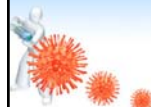
- Difficult to treat
- Multiple infections destroy heart valves
- Increase congestive heart failure
- Injection of crushed tablets – increase valve damage
- Injection of stimulants – increase valve damage



©Dr. Morris Berkstein, 2017

Case 4

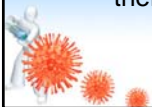
- Presents to ER short of breath, pedal edema and febrile
- CD4 25
- BP 88/45
- Admitted – echo shows large vegetation on aortic valve



©Dr. Morris Berkstein, 2017

Infective Endocarditis

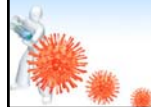
- If history of IE or murmur on exam then cardiac echo is warranted
- Increased congestive heart failure
- Edema – common also in liver failure as well
- Usually need 6 weeks iv antibiotic therapy



©Dr. Morris Berkstein, 2017

Case 4


- 2 week stay in ICU
- Patient codes – unsuccessful resuscitation



©Dr. Morris Berkstein, 2017

COPD

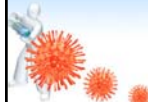
- Most have a history of smoking
- Seems earlier onset in addiction population
- Most start smoking at a young age
- Age 8 – 10 for many



©Dr. Morris Berberth, 2017

Talc Lung


- Talc induced granulomas mainly caused by injection of tablets
- Results in pulmonary hypertension and cor pulmonale
- Cure usually lung transplant



©Dr. Morris Berberth, 2017

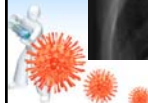

COPD

- High dose methadone can interfere with breathing
- Suboxone is often the better choice
- Low dose methadone in palliative setting very helpful



©Dr. Morris Berberth, 2017


Talc Lung



©Dr. Morris Berberth, 2017

COPD

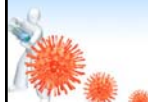
- Due to decreased mobility due to dependence on oxygen – carries may be granted earlier



©Dr. Morris Berberth, 2017

Pulmonary emboli

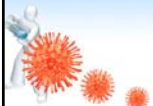
- Septic emboli
- Common with tricuspid endocarditis
- Life threatening



©Dr. Morris Berberth, 2017

Mortality

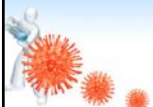
- High mortality rates
- Recent research shows life span in the US is now lower due to increasing deaths secondary to overdoses



© CDC, Maria Montessori, 2017

Mental Health

- Multiple comorbidities
- Crystal meth use bringing out more psychosis



© CDC, Maria Montessori, 2017